

Combined effects of errors in frontal-view asymmetry diagnosis

Pertti Pirttiniemi, Juha Miettinen and Tuomo Kantomaa

University of Oulu, Finland

SUMMARY The aim of the present investigation was to determine the relative extent of geometric error and errors in point identification in postero–anterior roentgenography. In one series of tests a group of dry human skulls was used, and the same cephalometric landmarks were identified twice by two orthodontists, using postero–anterior roentgenographs, first using the dry skulls as such, and then the same skulls with metal markers inserted to show the exact locations of the cephalometric points. Consistency and normal variation in the reproducibility of head position in the cephalostat between repeated roentgenographs were studied by a photographic technique in a group of young healthy adults, measuring the extent of minor head movements. Geometric error was calculated using a computer-aided design program (CAD) by rotating the three-dimensional co-ordinates of the cephalometric landmarks and thus obtaining projection error in the frontal view.

Accuracy in cephalometric point identification was best in dental landmarks and vertical orientation of superior orbital margins. Geometric error was least when landmarks near the anterior midsagittal plane, such as upper and lower dental midlines or point gonion were compared with each other. Width measurements from frontal-view cephalograms are most sensitive to minor movements in head posture. Due to combined errors, the use of width measurements in facial asymmetry diagnosis should not be used since variance in errors in landmark identification can be larger than that in actual landmark location.

Introduction

Postero–anterior roentgenographs have been widely used to study craniofacial asymmetries (Letzer and Kronman, 1967; Shah and Joshi, 1978; Alavi *et al.*, 1988; Peck *et al.*, 1991; Schmid *et al.*, 1991). The increasing trend towards bimaxillary orthognathic surgery has increased the practice of using projections other than the usual lateral-view roentgenographs (Jacobson, 1990; Proffit, 1991). Measurement of asymmetry from frontal-view roentgenographs is difficult, however, as pointed out by Persson (1973) and Cook (1980). Minor errors can arise from slight head rotation in the cephalostat and hence the midsagittal line of the skull may not be positioned as desired, perpendicular to the central X-ray. The situation becomes even more difficult when the aim is to measure degrees of asymmetry in subjects with severe asymmetries of basic structures, because in skulls with marked asymmetries it is

difficult to find a straight reference line. Even so, use of a cephalostat for frontal-view roentgenography usually involves the assumption that the trans-porionic axis is perpendicular to the midsagittal line of the skull, which may not be true in all cases.

So far attempts to identify sources of errors in the frontal view have been limited to investigations of errors relating to cephalometric point identification (El-Mangoury *et al.*, 1987). No attempt has been made to discover the extent of geometric error using different measuring points, or the relationship of geometric error to errors in point identification.

The aim of the present examination was to measure errors relating to incorrect identification of cephalometric points and to determine normal variation in head posture in a cephalostat between repeated recordings, and its effect on geometric error in frontal-view roentgen- cephalometry.

Subjects and methods

Dry human skulls ($n=20$) with no pathological deformations from the same ethnic group were used for roentgencephalometric examination. The origins of the skulls have been described by Koski (1948). All skulls had complete or almost complete dentitions. Occlusions of the skulls were fixed rigidly to maximal intercuspitation.

Reproducibility of head positioning in a cephalostat was measured with the co-operation of 20 healthy students of both sexes (12 female, 8 male, aged 22–36 years). The subjects were photographed repeatedly in the cephalostat, both in frontal and lateral projections.

Roentgencephalometric methods

Cephalograms of the dry skulls were taken in a cephalostat, using Trimax (Kodak) film. Exposures were made using a film-focus distance of 190 cm, the linear enlargement being 5.5 per cent for points situated near the transmeatal axis in frontal-view roentgenographs. The skulls were first roentgenographed in the cephalostat in the frontal view, and subsequently in the lateral view, with Frankfort plane horizontal in both projections. In the frontal view the central ray was directed perpendicular to the transmeatal axis and along the transmeatal axis for the frontal view. After taking the first set of roentgenographs, all points used in the analysis (Figures 1 and 2) were marked with metal wires or implants. All skulls were then roentgenographed a second time, using the same technique as before.

Reproducibility of head positioning

To test the reproducibility of head positioning in a cephalostat, the subjects were photographed twice, both in frontal and lateral projections and four photographs of each subject were taken in total. The interval between repeated photographs was 1 hour. Changes in head position were determined by using external fixed markers as measurement points on the nose and outer ear (Figures 3 and 4). Head tilt in the frontal view was measured by determining changes in interpupillary axis, the rigid head-holder of the cephalostat and its ear-rods forming a reference (Figure 3). Changes in the head position were recorded by digitizing the measurement points, using the tangent to the left and right ear-rods as the x co-ordinate.

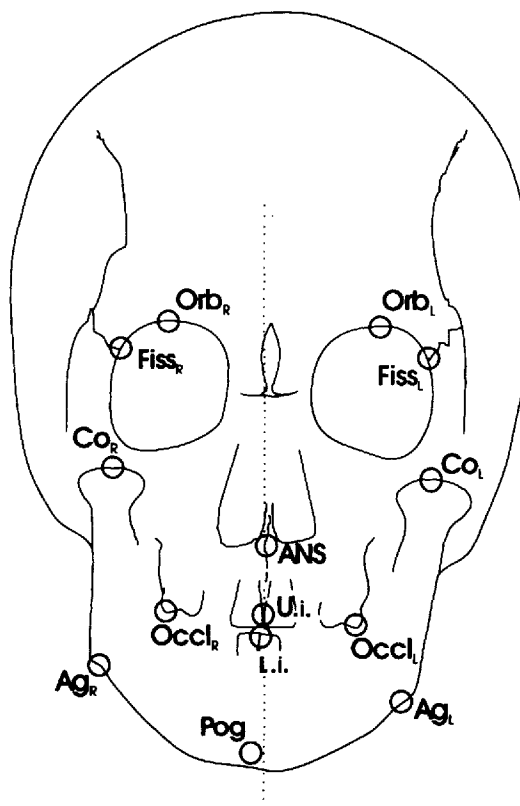


Figure 1 Measured points on P.A. roentgenograms. The vertical reference line intersects the anterior nasal spine (ANS) and is parallel to the true vertical line. Fiss_{r,l} The right and left intersections of the fronto-zygomatic sutures and the margins of the orbital cavity in the frontal view, Orb_{r,l} Extreme superior bilateral orbital margins, Co_{r,l} Extreme superior points of the right and left condylar heads, ANS Anterior nasal spine, Occl_{r,l} The lowermost tips of the buccal cusps of the right and left maxillary molars, U.i. The upper incisal midpoint, L.i. The lower incisal midpoint, Ag_{r,l} Antegonial notches, Pog The pogonion

Analysis of methodological errors

To assess the effect of geometric error resulting from minor variations in head posture on total methodological error in postero-anterior roentgenography, cephalometric findings were analysed using a modification of the three-dimensional roentgenographic method developed by Eliasson *et al.* (1982) and Ahlqvist *et al.* (1986) using a computer-aided design (CAD) program.

The measurement points in the postero-anterior roentgenographs (Figure 1) of the dry skulls were first given digital coordinates in two

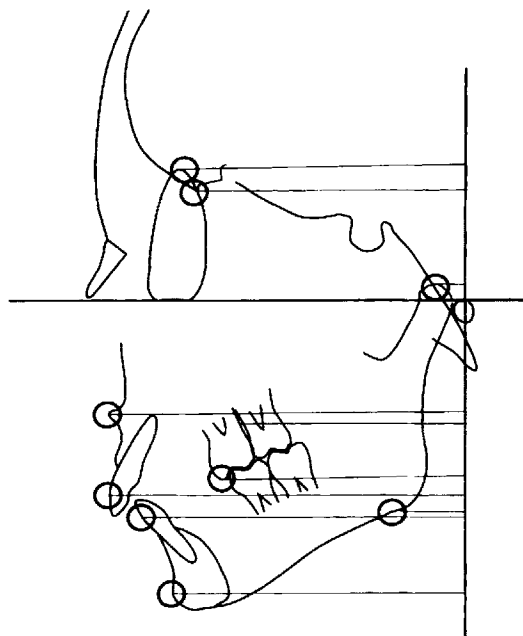


Figure 2 Reference points on lateral-view roentgenographs: Extreme superior orbital margins; the intersections of the fronto-zygomatic sutures and the margins of the orbital cavity; extreme superior points of the condylar heads; anterior nasal spine; the lowermost tips of the buccal cusps of the maxillary molars; the upper incisal midpoint; the lower incisal midpoint; antegonial notches; the gonion. The sagittal location of each point was measured as a distance to a vertical line passing the ear-rods, parallel to the Frankfort horizontal line.

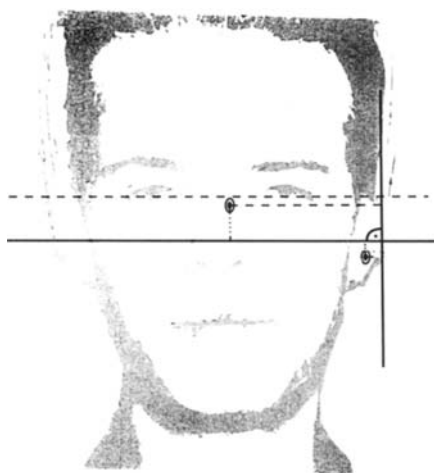


Figure 3 The change in head position in the frontal view was measured from the difference between two photographs where the ear-rods and the interpupillary axis served as the reference lines.

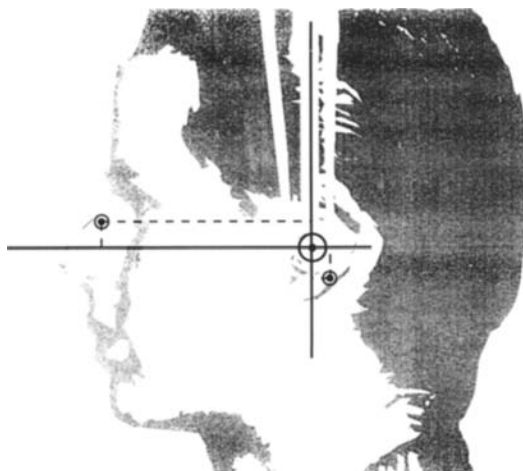


Figure 4 The change in head position in the lateral view was measured from the difference between two photographs where fixed markers on the nose and the outer ear on the left side were the measurement points, the rigid cephalostat serving as the reference. True three-dimensional angular change in head position was obtained using a computer-aided design program.

dimensions by two calibrated orthodontists (PP and JM). The researchers calibrated the method by practising together the procedure before the final analysis. Roentgenographs taken in the lateral projection in the same cephalostat as the poster-anterior roentgenographs were measured (Figure 2), and the location of the points in three dimensions could be determined, using x , y , z co-ordinates. The points were then rotated artificially using the computer program to calculate effects of changing head position on total geometric error (Figure 5). The geometric error was measured as the absolute change in the distance of the lateral co-ordinate of the cephalometric point to the midline when the head was rotated artificially around the vertical axis. The rotation around the vertical axis was studied here, since comparison of lateral discrepancies between sides of the face is most sensitive to this type of movement.

Statistical analyses

The significances of differences between means of errors for the different recording methods (roentgencephalometry with and without metal markers) were determined by using the t -test for paired observations. The use of the parametric test was based on the assumption that the sample was normally distributed.

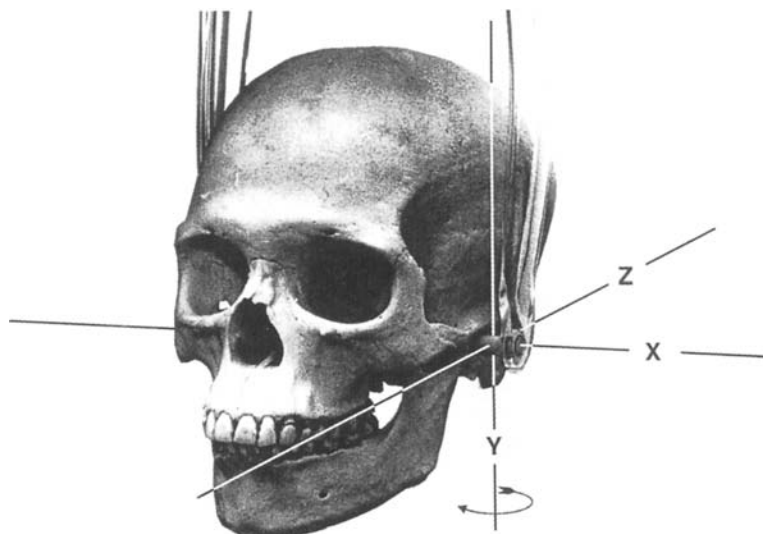


Figure 5 The effect of lateral geometric error on cephalometric points used in postero-anterior roentgenography was calculated using a computer-aided design program, by artificially rotating the three-dimensional co-ordinates of the cephalometric landmarks around the vertical rotation axis (passing vertically the left ear-rod).

The inter-examiner error in cephalometric measurements was determined by the formula: $s(\text{inter-examiner}) = \sqrt{\sum d^2 / 2n}$, where d is the difference between repeated measurements and n is the number of determinations per each examiner.

The same basic formula was applied to determine the intra-examiner error for the measurement of the head position from photographs: $s(\text{intra-examiner}) = \sqrt{\sum d^2 / 2n}$, where d is the difference between repeated measurements and n is the number of duplicate determinations per examiner. To assess the importance of the intra-examiner error, the error variance $s^2 = [s(\text{intra-examiner})]^2$ was studied in relation to the variance for the entire material representing the biological variation (Mitgård *et al.*, 1974).

The Statview II and Statworks programs for Apple Macintosh computer were used for statistical analyses. Geometric error was studied using the the Auto-CAD[®] (MS-DOS version) computer program to calculate effects of changing head position on total geometric error.

Results

The mean inter-examiner error was lowest in lateral co-ordinates of midline points describing the location of anterior nasal spine (ANS) and upper and lower incisal midlines (U.i._x, L.i._x) and point pogonion (Pog_x). In the vertical co-ordinates lowest errors were in the measurements of the bilateral location of superior orbital margins (Orb L_y, Orb R_y) (Table 1).

The mean error was higher in other vertical parameters like in vertical coordinates of fronto-zygomatic suture (Fiss_y), Pog (Pog_y), Condyle (Co_y) and also in upper and lower incisal mid-points (U.i._y, L.i._y) (Table 1).

When the inter-examiner error between the roentgenographs from plain skulls and those taken with the metal markers were compared, the error was significantly decreased, when using the metal markers, in the lateral location of superior orbital margin ($P < 0.05$), in the vertical location of fronto-zygomatic suture ($P < 0.05$), in the vertical location of point pogonion ($P < 0.01$), in the vertical ($P < 0.001$) and horizontal locations ($P < 0.01$) of condylar points

Table 1 Mean inter-examiner difference (in mm) in cephalometric point identification in frontal-view roentgenography in 20 human dry skulls and with and without metal markers inserted in cephalometric landmarks.

	Dry skulls				Dry skulls with metal markers				
	x	SD	95% confidence intervals		x	SD	95% confidence intervals		P
OrbR _x	1.7	1.92	0.8	2.6	0.6	0.70	0.3	0.9	<0.05
OrbR _y	0.5	0.65	0.4	0.8	0.4	0.54	0.1	0.6	NS
OrbL _x	2.1	1.86	1.1	3.1	0.8	0.83	0.4	1.2	NS
OrbL _y	0.5	0.45	0.2	0.8	0.6	0.80	0.2	1.0	<0.025
FissR _x	1.7	2.04	0.7	2.7	1.0	0.86	0.6	1.4	NS
FissR _y	2.5	2.55	1.3	3.5	0.6	0.54	0.3	0.8	<0.01
FissL _x	1.7	0.33	1.1	2.3	1.3	1.03	0.8	1.8	NS
FissL _y	2.3	2.4	1.2	3.4	1.0	1.0	0.5	1.5	<0.025
ANS _x	0.3	0.23	0.2	0.5	0.5	0.44	0.3	0.7	NS
ANS _y	1.8	1.54	1.0	2.5	1.1	1.15	0.5	1.6	NS
U.i. _x	0.5	0.49	0.2	0.7	0.3	0.38	0.1	0.5	NS
U.i. _y	0.9	0.75	0.6	1.3	1.1	0.80	0.7	1.5	NS
L.i. _x	0.3	0.34	0.4	0.9	0.4	0.37	0.3	0.6	NS
L.i. _y	1.3	1.3	0.7	1.9	0.9	0.10	0.5	1.4	NS
Pog _x	0.4	0.42	0.2	0.6	0.5	0.54	0.2	0.7	NS
Pog _y	2.4	1.62	1.6	3.1	1.0	0.79	0.6	1.4	<0.05
CoR _x	2.7	2.27	1.6	3.7	0.1	0.21	0.0	0.2	<0.001
CoR _y	2.9	2.25	1.8	3.9	0.6	0.72	0.2	0.9	<0.001
CoL _x	4.6	2.63	3.3	5.8	0.3	0.34	0.1	0.4	<0.001
CoL _y	1.7	1.41	1.0	2.4	0.4	0.49	0.2	0.7	<0.001
OcclR _x	1.0	1.35	0.3	1.6	1.2	0.77	0.8	1.4	NS
OcclR _y	1.5	1.6	0.8	2.3	0.7	0.54	0.4	0.9	<0.05
OcclL _x	0.9	1.50	0.2	1.6	1.5	1.32	0.9	2.1	NS
OcclL _y	1.5	1.55	0.8	2.3	1.0	1.14	0.5	1.6	NS
AgR _x	2.6	2.28	1.6	3.7	1.4	0.99	0.9	1.8	<0.025
AgR _y	2.2	2.01	1.3	3.2	1.0	0.84	0.6	1.3	<0.01
AgL _x	2.4	2.21	1.4	3.4	1.1	1.09	0.6	1.6	<0.01
AgL _y	2.3	1.98	1.4	3.2	0.9	0.84	0.5	1.3	<0.01

t-test for paired observations.

and in the vertical ($P<0.01$) and horizontal ($P<0.05$) location of point antegonion (*t*-test).

In the analysis of reproducibility of head position in the cephalostat, the largest movement was measured in the rotation around the vertical axis (mean rotation 2.6 degrees, range 0.5–7.0 degrees), and the smallest movement in the head tilt as measured in the frontal view (mean tilt 1.4 degrees, range 0.0–3.0 degrees) (Table 2).

An effect of head rotation around the vertical axis on the level of mean lateral geometric error at the recording points is presented in Figure 6 and in combination with the mean inter-examiner error in Figure 7. The lowest level of geometric error, measured as the change in the distance of the lateral co-ordinate of the point to midline, was recorded in landmarks near the anterior midsagittal plane, when upper and lower dental midlines and point menton were

Table 2 Variation in head position (in degrees) in the cephalostat head holder between two recordings in three dimensions with an interval of 1 hour, and the intra-examiner error calculated from ten duplicate recordings of variables showing the head position. S^2 denotes the variance in the angulation showing the head position in the whole sample.

	<i>x</i>	SD	range	s(intra-examiner)	s(intra-examiner) ² % of S^2
Head rotation (axial)	2.6	2.21	0.5–7.0	0.3	2.6
Head tilt (lateral view)	2.5	2.41	0.0–7.0	0.5	1.1
Head tilt (frontal view)	1.4	1.26	0.0–3.0	0.5	5.0

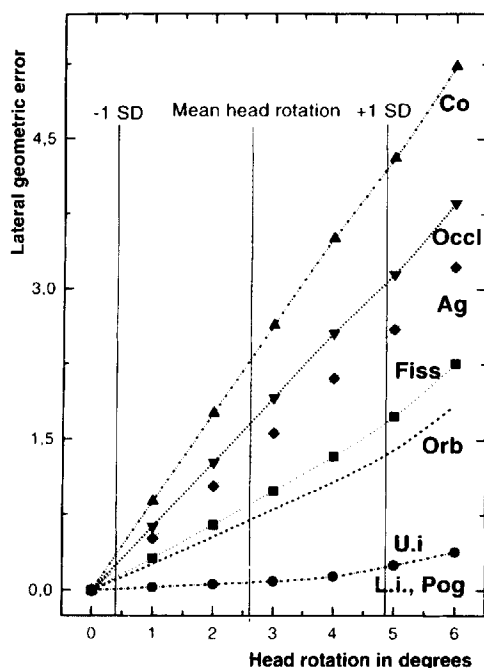


Figure 6 The level of lateral geometric error of cephalometric points (in mm) used in postero-anterior roentgenography in relation to the head rotation in the cephalostat. The value of mean head rotation (± 1 SD) refer to the data derived from the study of variation in head position in the cephalostat head holder between two recordings (Table 2).

compared with a vertical line in the anterior midsagittal area (a line passing the anterior nasal spine). The largest geometric errors were

recorded in linear measurements of most laterally existing points (Figures 6 and 7).

Discussion

Roentgenography is subject to various sources of error. Overall error can be broken down into components (Carlsson, 1967; Baumrind and Frantz, 1971a, b; Houston *et al.*, 1986). The components include geometric errors and errors resulting from incorrect location of points. Errors in relation to point location in lateral view have variously been studied, and it has generally been concluded that the greatest error is due to false point identification while the geometric error and various technical radiographic errors tend to be smaller and in many cases can even be ignored (Baumrind and Frantz, 1971a, b; Houston *et al.*, 1986; Ahlqvist *et al.*, 1986). van Aken (1963), nevertheless pointed to a special group of patients, those with skull asymmetry and rotation of the head, showing theoretically that the geometric error can exceed the other errors in lateral view if the asymmetry is great enough and if the patient is not positioned perpendicular to the true median plane of the skull.

The relationship between sources of error is, however, less evident for frontal projection and postero-anterior roentgenography. The variation in the inter-examiner point identification was in the present investigation relatively large and the degree of error varied greatly according to the point concerned, and to the vertical and horizontal orientations of the measured dis-

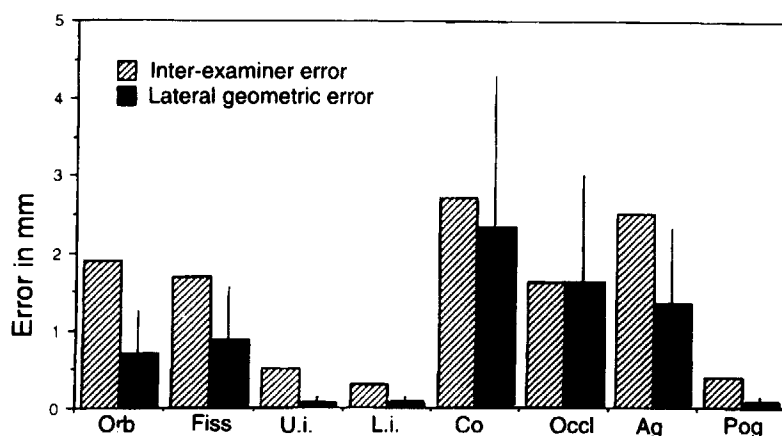


Figure 7 The level of inter-examiner error in the identification of cephalometric points used in postero-anterior roentgenography and the lateral geometric error (± 1 SD) due to mean head rotation in the cephalostat.

tances. The results are in this respect in accordance with those of El-Mangoury *et al.* (1987). When the level of identification error in frontal-view roentgenography is concerned, the level of error in some points is, however, considerably lower, e.g. in the lateral co-ordinate of anterior nasal spine and upper and lower incisal midlines and point pogonion, and the use of metal markers did not increase accuracy of location of these landmarks. This may be because frontal-view recordings give the location of a single point whereas lateral-view recordings are often based on bilateral points which are measured as a single point or line, as in the case of mandibular gonial and condylar points. In the case of other skull and mandibular points in the frontal view, for example condylar points and frontozygomatic suture points, the level of error rises sharply, however, and general use of these points for accurate measurements cannot be recommended.

Geometric error due to head rotation in the cephalostat was greatest in relation to lateral co-ordinates of the most laterally located cephalometric points. The level of geometric error remains considerably low when dental and skeletal midline points located in the anterior midsagittal portion of the face are compared with each other. This is because errors in relation to measurement point and reference point were equal, and they can therefore be accepted, even though the absolute geometric error would be relatively high due to altered position of the head in the cephalostat. Thus the method suggested by Svanholt and Solow (1977) for measurement of dental and anterior facial midline asymmetries can be recommended, because it excludes many sources of errors which become evident when comparing, e.g., left and right facial areas.

In the diagnosis of asymmetries, geometric error can be minimized by comparing dental and skeletal horizontal lines as far as the levels compared are located in the anterior facial area. The use of comparisons between facial horizontal lines for examination of asymmetries have recently been suggested by Proffit (1991) in the treatment planning of orthognathic surgery. The results reported here support the use of such analyses.

Inter-examiner error in the identification of many cephalometric points in this study was relatively high. If one person had undertaken duplicate determinations, levels of error would

probably have been less, as the individual way to identify and measure certain point is to some extent constant. In cephalometry this phenomenon can be included in systematic errors (Houston, 1983) due to its directional nature. On the other hand, on the basis of the present findings, it is not recommended to make metric comparisons between the results of different cephalometric studies based on frontal view roentgenographs, because considerable difference between the results may originate from the individual way of point identification.

Width measurements from frontal-view cephalograms are most sensitive to minor movements in head posture and their use in asymmetry diagnosis are not recommended. Errors in point identification and geometric error together may be too great to make proper diagnosis of facial asymmetry. However, this does not lessen the need for use of frontal-view roentgenographs to study asymmetry, but asymmetry recorded in an individual should be regarded as relative to a reference point or line that may itself be asymmetrically positioned. This is obvious in the cases of severe asymmetries, where every structure in the craniofacial skeleton may to some extent be distorted and thus asymmetrically positioned. Diagnoses of asymmetry should be verified by means of clinical analysis because of the possibility that geometric error may be a major factor affecting the parameters. To reduce the effect of geometric errors in postero-anterior cephalometry, a reference line and measurement points should be chosen as close to each other transversely and sagittally as possible, e.g. near the anterior midsagittal plane.

Other diagnostic methods for asymmetric development need to be developed. The image-analysis methods used for lateral-view roentgenography could be used for frontal-view analysis, reducing errors relating to individual point identification. A computer-aided system to correct the errors arising from variations in head position in the cephalostat or asymmetric skull bases might be developed for use in examination of severely asymmetric patients.

Acknowledgements

This research was supported by the Academy of Finland, Grant 1051212. We would like to thank voluntary dental students Taina

Paloniemi and Minna Mehtälä for their help during the research and Mr. Antti Jaatinen of the Department of Mechanical Engineering, University of Oulu, for his collaboration in developing a computerized system for the cephalometric error analysis.

Address for correspondence

Pertti M Pirttiniemi, DDS; PhD
Department of Orthodontics,
Institute of Dentistry,
University of Oulu,
SF-90220 Oulu, Finland

References

- Ahlqvist J, Eliasson S, Welander U 1986 The effect of projection errors on cephalometric length measurements. *European Journal of Orthodontics* 8: 141–148
- Alavi D G, BeGole E A, Schneider B J 1988 Facial and dental arch asymmetries in Class II subdivision malocclusion. *American Journal of Orthodontics and Dentofacial Orthopedics* 93: 38–46
- Baumrind S, Frantz R C 1971a The reliability of head film measurements. 1. Landmark identification. *American Journal of Orthodontics* 60: 111–127
- Baumrind S, Frantz R C 1971b The reliability of head film measurements. 2. Conventional angular and linear measures. *American Journal of Orthodontics* 60: 505–517
- Carlsson G E 1967 Error in X-ray cephalometry. *Odontologisk Tidskrift* 75: 99–129
- Cook J T 1980 Asymmetry of the craniofacial skeleton. *British Journal of Orthodontics* 7: 33–38
- Eliasson S, Welander U, Ahlqvist J 1982 The cephalographic projection. *Dentomaxillofacial Radiology* 11: 117–122
- El-Mangoury N H, Shaheen S I, Mostafa Y A 1987 Landmark identification in computerized posteroanterior cephalometrics. *American Journal of Orthodontics and Dentofacial Orthopedics* 91: 57–61
- Houston W J B 1983 The analysis of errors in orthodontic measurements. *American Journal of Orthodontics* 83: 382–390
- Houston W J B, Mahler R E, McElroy D, Sherriff M 1986 Source of error in measurements from cephalometric radiographs. *European Journal of Orthodontics* 8: 149–151
- Jacobson A 1990 Planning for orthognathic surgery – art or science? *International Journal of Adult Orthodontics and Orthognathic Surgery* 5: 217–223
- Koski K 1948 A study on the alveolar arches of the Lapps. Thesis, University of Helsinki
- Letzer G, Kronman J 1967 A posteroanterior cephalometric evaluation of craniofacial asymmetry. *Angle Orthodontist* 37: 205–211
- Mitgård J, Björk G, Linder-Aronson S 1974 Reproducibility of cephalometric landmarks and errors of measurement of cephalometric cranial distances. *Angle Orthodontist* 44: 56–61.
- Peck S, Peck L, Kataja M 1991 Skeletal asymmetry in esthetically pleasing faces. *Angle Orthodontist* 61: 43–47
- Persson M 1973 Mandibular asymmetry of hereditary origin. *American Journal of Orthodontics* 63: 1–11
- Proffit W R 1991 Treatment planning. In: Proffit W R, White R P (eds.) *Surgical-orthodontic treatment*, C V Mosby, St.Louis, pp. 142–192.
- Schmid W, Mongini F, Felisio A 1991 A computer-based assessment of structural and displacement asymmetries of the mandible. *American Journal of Orthodontics and Dentofacial Orthopedics* 100: 19–34
- Shah S M, Joshi M R 1978 An assessment of asymmetry in the normal craniofacial complex. *Angle Orthodontist* 48: 141–148
- Svanholt P, Solow B 1977 Assessment of midline discrepancies on the postero-anterior cephalometric radiograph. *Transactions of the European Orthodontic Society*, pp. 261–265
- van Aken J 1963 Geometric errors in lateral skull X-ray projections. *Nederlands Tijdschrift voor Tandheelkunde* 70: 18–30